

Long-term weekly adrenocorticotrophic hormone therapy for relapsed infantile spasms

Takeo Kato^{1*}, Minako Ide¹ and Masatoshi Nakata²¹Department of Pediatrics, Hyogo Prefectural Amagasaki General Medical Center, Hyogo, Japan²Department of Pediatrics, Graduate School of Medicine, Kyoto University, Kyoto Japan

Article Info

Article Notes

Received: October 22, 2016

Accepted: December 16, 2016

*Correspondence:

Takeo Kato, Department of Pediatrics, Hyogo Prefectural Amagasaki General Medical Center, 2-17-77 Higashinabacho, Amagasaki city, Hyogo, 660-8550, Japan, Tel: +81-6-6480-7000; Fax: +81-6-6480-7001; E-mail: tkokt4819@gmail.com

© 2016 Takeo Kato. This article is distributed under the terms of the Creative Commons Attribution 4.0 International License.

Keywords

ACTH

Long-term weekly ACTH therapy

Infantile spasms

Relapse

Epileptic spasms

Hypsarrhythmia

Cognitive function

ABSTRACT

Infantile spasms (IS) is the most recognized epileptic encephalopathy in early infancy, resulting in poor cognitive outcome. Adrenocorticotrophic hormone (ACTH) therapy is the first-line therapy for IS, but the relapse rate is high. Relapse after initial ACTH therapy is a poor prognostic factor for long-term seizure control and outcome of cognitive function. Recently, several studies have reported on the long-lasting maintenance of the positive effects produced by an initial course of ACTH by using long-term weekly ACTH therapy for relapsed IS. Here, we review the clinical characteristics of five previously reported cases. Epileptic spasms and hypsarrhythmia remained completely resolved during the extended ACTH therapy and did not recur after ACTH discontinuation in all cases. Furthermore, no cognitive or neurodevelopment deterioration was observed, and no serious adverse events occurred in any patient. In conclusion, this therapy appears safe and may lead to improved psychomotor development. We believe that it may be a good alternative therapy when frequent relapses occur after a favorable response to an initial course of conventional ACTH therapy. However, further studies are required to examine the risks and benefits of this therapy for relapsed IS in a large population and in countries in addition to Japan.

Main text

Infantile spasms (IS), or West syndrome is the most recognized epileptic encephalopathy in early infancy, resulting in poor cognitive outcome¹⁻⁵. The incidence of IS is estimated to be about 1 per 2000 to 4000 live births^{4,5}. The disorder presents with a unique seizure type, epileptic spasms (ES), a characteristic electroencephalography (EEG) pattern called hypsarrhythmia, and psychomotor delay/regression. Developmental outcome is poor in patients with IS, and a majority of patients have moderate or severe mental retardation. The most important prognostic factors include the etiology of IS and the duration of hypsarrhythmia. Early control of hypsarrhythmia is crucial for improved neurodevelopmental prognosis^{6,7}, and a recent study demonstrated that the risk of lower mental outcome in IS increases after 3 weeks duration of hypsarrhythmia⁷. Another prognostic indicator, sustained response to therapy without relapse, is also associated with favorable prognostic outcomes⁸. Thus, the goal of the treatment for IS should be to produce not only cessation of spasms but also resolution of hypsarrhythmia as rapidly as possible.

Evidence does not support the clinical efficacy of most conventional anti-epileptic drugs (AEDs) as effective treatments for IS⁸. The American Academy of Neurology and the Child Neurology Society concluded that natural or synthetic adrenocorticotrophic

hormone (ACTH) therapy is probably effective for short-duration treatment of IS and resolution of hypsarrhythmia⁹. Several studies have reported that the clinical response to ACTH therapy in 42–87% of patients within 2 weeks occurred without major adverse side effects, but relapse rate is high (from 30% to 72%)^{1,10-16}. Matsumoto et al. reported that relapse after initial ACTH therapy is a poor prognostic factor for long-term seizure control¹⁷. Riikonen et al. showed that a second course of ACTH controls IS in only 23% of relapsed IS patients after the first course of ACTH therapy¹⁸. Thus, one problem with conventional ACTH therapy is a high relapse rate. Recently, several studies have reported that a successful alternative therapy, namely, long-term weekly ACTH therapy for relapsed IS after the first conventional ACTH therapy, resolves this problem¹⁹⁻²¹. The aim of this therapy is to maintain the positive ACTH effects for a long time. Okanishi et al. first reported successful long-term ACTH therapy in three patients with relapsed IS¹⁹. Inui et al. then reported one case²⁰. We reported successful long-term weekly ACTH therapy for relapsed IS after conventional ACTH therapy in a child with tuberous sclerosis complex (TSC)²¹.

In our case, the patient had a series of ES and hypsarrhythmia (Figure 1A) at the age of 3 months. She was diagnosed with IS associated with TSC, and was treated with conventional synthetic ACTH therapy (0.005 mg/kg daily for 2 weeks) at 4 months of age, and a second course of ACTH therapy (0.01 mg/kg daily for 2 weeks) at 8 months of age. We could not use Vigabatrin (VGB), because this drug had not been approved for use in Japan at the point of the study. Both courses were transiently effective, but the patient relapsed. A third course of ACTH therapy (0.01 mg/kg daily for 2 weeks) was begun at age 1 year and 2 months, and long-term weekly ACTH therapy (0.01 mg/kg weekly) was continued thereafter. During this extended therapy, both ES and hypsarrhythmia remained completely resolved (Figure 1B). Therapy was continued, and dose reduction was started when the patient was 2 years and 10 months old. The AED treatment regimen did not change during long-term weekly ACTH therapy. No serious adverse events, including hypertension, infection, and irritability occurred during this therapy. Three months after discontinuing ACTH therapy, the patient developed tonic seizures; however, the attacks were well controlled by administering a combination of lamotrigine and valproate. Although focal epileptic discharges remained on EEG, no relapse of ES or hypsarrhythmia was observed afterwards (Figure 1C), and topiramate treatment was discontinued. The patient was able to stand without support and speak some words by 1 year and 5 months of age. Her developmental quotient scores were 54 and 53 at 1 year and 8 months and at 3 years and 8 months of age, respectively.

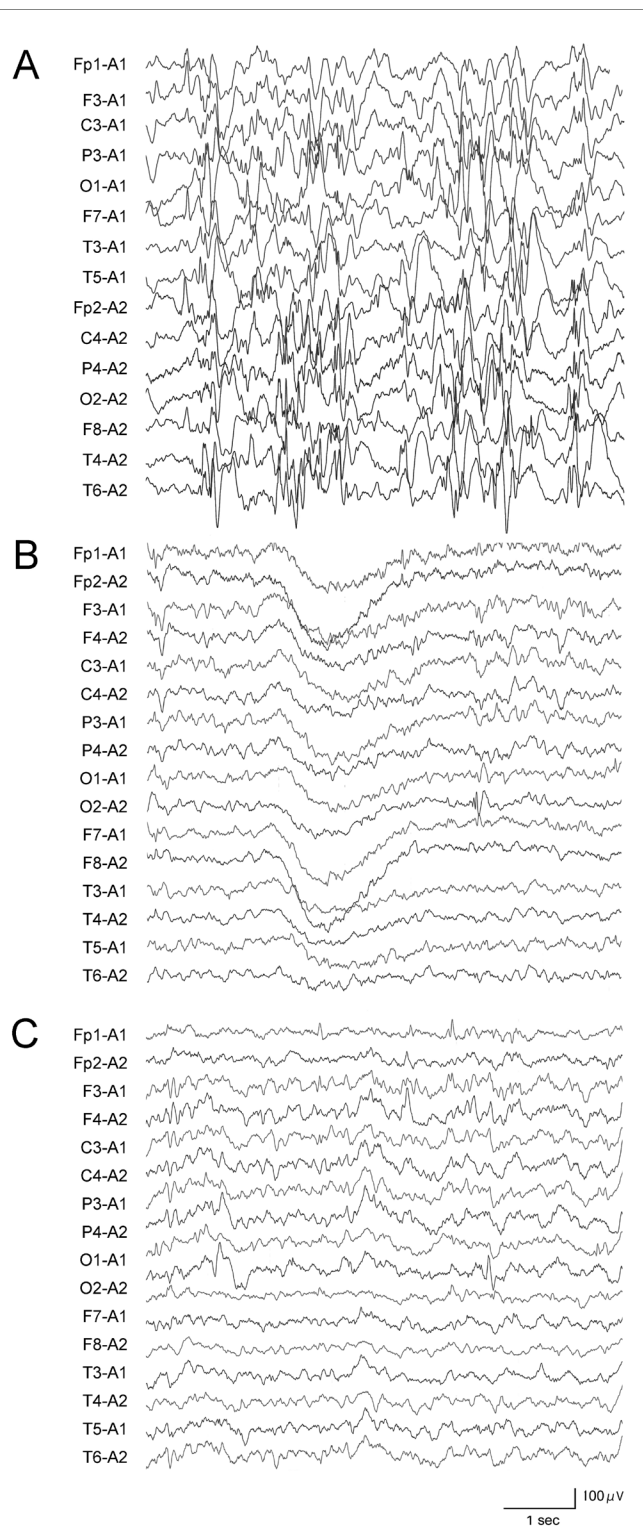


Figure 1: Interictal sleep EEG of the case 5

The EEG data revealed hypsarrhythmia at initial presentation (A), rare spikes in the occipital regions during long-term ACTH (B) and at age 3 years (C). Interictal EEGs were done by every 6 months during and after the long-term ACTH therapy both.

The clinical characteristics of five previously reported cases, including ours, are summarized in Table 1. Because

	1	2	3	4	5	
Reference	Ref.19. Okanishi, et al. 2008.	Ref.19. Okanishi, et al. 2008.	Ref.19. Okanishi, et al. 2008.	Ref.20. Inui, et al. 2014.	Ref.21. Nakata, et al. 2016.	
Etiology	multiple anomalies	Preterm infant, porencephaly	Unknown	Lissencephaly (LIS1)	TSC	
Age at onset of spasms	1 mo	1 y and 3 mo	1 y and 6 mo	2 mo	3 mo	
Conventional ACTH therapy	1 time	1 time	1 time	1 time	2 times	
Treatment before ACTH therapy	VitB6, NZP, VPA, VGB, CZP	VitB6, NZP, ZNS, VPA, CBZ	VitB6, PB, VPA, CBZ, ZNS, CZP	PB	VitB6, VPA VPA, TPM	
Age at start	4 mo	1 y and 6 mo	1 y and 6 mo	3 mo	4 mo 8 mo	
Dosage	0.025 mg/kg daily for 14 d 0.025 mg/kg every 2 d x 3	0.01 mg/kg daily for 14 d 0.01 mg/kg every 2 d x 3	0.0125 mg/kg daily for 14 d 0.0125 mg/kg every 2 d x 3	0.015 mg/kg daily for 14 d 0.015 mg/kg every 2 d for 7 d 0.0075 mg/kg every 2 d for 7 d	0.005 mg/kg daily for 14 d 0.005 mg/kg every 2 d for 7 d 0.005 mg/kg every 3 d for 7 d	0.01 mg/kg daily for 14 d 0.01 mg/kg every 2 d for 7 d 0.01 mg/kg every 3 d for 7 d
Efficacy on spasms	Spasms ceased on 5th day	Spasms ceased on 8th day	No convulsions during therapy	Spasms ceased on 4th day	Spasms ceased on 6th day Spasms ceased on 2nd day	
Efficacy on EEG	Hyps disappeared on 3rd day	Hyps partially reduced	Hyps disappeared on 6th day	-	Hyps disappeared on 12th day -	
Relapse	during withdrawal stage	5 mo	2 mo	8 mo	2 mo 2 mo	
Treatment after relapse	TRH, Ketogenic diet, liposteroid, NZP	NZP, CBZ	CZP	VPA, CZP, ZNS, TPM	TPM -	
Long-term weekly ACTH therapy						
Age at start	1 y and 7 mo	2 y and 4 mo	2 y and 3 mo	11 mo	1 y and 1 mo	
Dosage	0.015 mg/kg daily for 14 d 0.015 mg/kg every 2 d for 14 d 0.015 mg/kg every 3 d for 14 d 0.015 mg/kg weekly	0.01 mg/kg daily for 21 d 0.01 mg/kg every 2 d x 3 0.01 mg/kg every 3 d x 3 0.01 mg/kg weekly	0.0135 mg/kg daily for 14 d 0.01 mg/kg every 2 d x 3 0.01 mg/kg every 3 d x 2 0.01 mg/kg weekly	0.015 mg/kg daily for 14 d 0.015 mg/kg every 2 d for 7 d 0.0075 mg/kg every 2 d for 7 d 0.015 mg/kg weekly	0.01 mg/kg daily for 14 d 0.01 mg/kg weekly	
Therapy period (Age)	1 y (2 y and 7 mo)	1 y (3 y and 4 mo)	7 mo (2 y and 10 mo)	1 y (1 y and 11 mo)	1 y and 9 mo (2 y and 10 mo)	
Efficacy on spasms	Spasms ceased on 4 wk	Spasms ceased on 11th day	Spasms ceased on 6th day	Spasms ceased on 6th day	Spasms ceased on 5th day	
Efficacy on EEG	Hyps disappeared on 4 wk	Hyps disappeared on 14th day	Hyps disappeared on 11th day	NA	Hyps disappeared on 7th day	
Adverse event	Transient mild cardiac hypertrophy, irritability, hyperphagia, oral candidiasis	No marked adverse effects	Transient fever, irritability, mild cardiac hypertrophy, weight gain	No marked adverse effects	No marked adverse effects	
Prognosis						
Seizure	GTS	GTS	No seizures	No seizures	GTS	
Interictal epileptic discharge	Focal epileptic discharge	Focal epileptic discharge	No epileptic discharge	Focal epileptic discharge	Focal epileptic discharge	
Psychomotor development	Improved	Improved	Improved	Improved	Improved	

Table 1: Clinical characteristics and schedules of conventional and long-term weekly ACTH therapy in five previously reported cases

Abbreviations: Y, year; mo, month; d, day; VitB6, vitamin B6; NZP, nitrazepam; VPA, valproate; VGB, vigabatrin; CZP, clonazepam; ZNS, zonisamide; CBZ, carbamazepine; PB, phenobarbital; TPM, topiramate; TRH, thyroid release hormone; GTS, generalized tonic seizure; All remaining abbreviations are defined in the main text.

all of these cases were reported in Japan, the ACTH preparation used was synthetic. The mean age at the start of treatment and the duration of long-term weekly ACTH therapy were 19.6 months (range, 11-28 months) and 12.8 months (range, 7-21 months), respectively. The ACTH preparation contained an extremely low dose, with a mean dose of 0.0127 mg/kg/dose (range, 0.01-0.015 mg/kg/dose) during long-term weekly ACTH therapy. During this therapy, no relapse was observed for ES and hypsarrhythmia on EEG; however, three cases developed generalized tonic seizures several months after therapy was discontinued. No neurodevelopment decline was observed during this treatment. In our aforementioned case, the developmental quotient score was maintained during long-term weekly ACTH therapy and thereafter. The results of previous studies suggested a poor prognosis of cognitive function and epilepsy was likely in our patient because she had IS with TSC and experienced frequent relapses^{22,23}. However, the resolution of both ES and hypsarrhythmia, which can damage the developing brain, may have improved her development. Thus, we suggested

in that report that long-term weekly ACTH therapy may be effective and used as an alternative treatment for relapsed IS. In all cases, the response to conventional ACTH therapy for both ES and hypsarrhythmia was good. Of the all five cases, ES was resolved within 1 week after the first ACTH course in four cases, and after the second ACTH course in three cases. These results suggested that a good response to conventional ACTH therapy may be important for successful long-term weekly ACTH therapy, because long-term ACTH weekly therapy may maintain the initial effects.

Several issues remain to be resolved when conducting long-term weekly ACTH therapy, one of which is the optimal treatment period. In four of the aforementioned cases, not our case, the duration of long-term weekly ACTH therapy was approximately 1 year. In our case, therapy was intended to be discontinued when the patient was 2 years old; however, because ES recurred, therapy was resumed. Thus, the duration of therapy in our case was approximately 2 years, as our patient discontinued ACTH therapy when she was 3 years old. We questioned

whether the key to successful long-term weekly ACTH therapy was the duration of this therapy. Okanishi et al. reported that all three of their patients were able to discontinue treatment at approximately 3 years of age, although the duration of therapy was 1 year¹⁹. In general, despite having a reputation of being difficult to treat, the spasms occurring in this condition tend to spontaneously resolve with age. ES disappears in 50% of children by the age of 3 years, and hypsarrhythmia is rare after 3 years of age^{3,24}. Considering that IS is an age-dependent, epileptic encephalopathy syndrome, we consider that the age up to which the patient receives long-term weekly ACTH therapy is more important than the duration of this therapy. Thus, we recommend continuing this therapy until the patient is 3 years of age, after which time the epileptic activity appears to be naturally suppressed.

An additional concern about long-term weekly ACTH administration is adverse effects. In general, ACTH therapy is associated with some adverse effects, including obesity, hypertension, hypertrichosis, cardiac myopathy, brain shrinkage, subdural hematoma, and immunosuppression, leading to lethal infection. However, during the ACTH therapy in our case and in the other cases examined here, no serious adverse events occurred. In two of the five cases, mild adverse effects were reported, including transient mild cardiac hypertrophy, irritability, hyperphagia, oral candidiasis, transient fever, irritability, and weight gain²⁵. In our case, the patient experienced chickenpox during therapy without severe manifestations. She had not been previously vaccinated, and the disease was resolved by standard antiviral treatment with acyclovir. She showed normal immunoglobulin levels throughout therapy, acquiring anti-varicella zoster immunoglobulin G after the infection. Thus, these results indicated the relatively safety of the therapy regarding immunosuppression; however, further studies should be conducted because chickenpox may be life-threatening in immunosuppressed patients. In the patient's endocrine system, her cortisol level was within the reference range, but her ACTH level was low (2.2 pg/ml; reference range 7.2 - 63.3 pg/mL). When the rapid ACTH test was carried out during long-term ACTH therapy, serum cortisol levels showed a normal response. Thus, we skipped the ACTH bolus when patients developed a fever and did not employ hydrocortisone replacement therapy. No obvious brain shrinkage was observed during therapy in our case. Additionally, because previous studies have used a synthetic ACTH preparation, the safety and efficacy of natural preparations are unknown.

Another concern is that we do not fully understand the impact of long-term weekly ACTH administration on the developing brain. Lorusso et al. reported low-dose synthetic ACTH therapy (ACTH analog tetracosactide; 1 mg intramuscularly once a week for 12 months)

of adult nephrotic patients (n=80). In their study, no neuropsychiatry adverse effects were reported. However, in another report, in which adult patients (n=20) with idiopathic membranous nephropathy were treated with a synthetic ACTH analog with a total treatment period of nine months and 59 injections (1mg/dose), neuropsychiatry adverse effects, including mood disorders and agitation, in 8 patients (40%), were observed. Because all cases examined here were symptomatic IS, it remains controversial whether this therapy should be applied to other relapsed IS cases, including cryptogenic IS. In conclusion, we reviewed the successful use of long-term weekly ACTH therapy for relapsed IS after a first course of conventional ACTH therapy. This therapy may have advantages over other conventional therapies because it has the potential of eliminating the risk of ES and hypsarrhythmia, which outweighs its potential adverse effects. We believe that this therapy has merits that could improve the quality of life and daily activities of patients, even in those with severe neurodevelopmental disabilities. Although it may be a good alternative therapy for patients with frequent relapses after a favorable response to conventional ACTH therapy, this therapy should be selected only if other treatments, including new AEDs such as vigabatrin, and epilepsy surgery, are not applicable or effective. Further studies will be required to determine whether the therapy has adverse effects on metabolic or endocrine systems to establish fully the safety of this therapy.

References

1. Lux AL, Osborne JP. A proposal for case definitions and outcome measures in studies of infantile spasms and West syndrome consensus statement of the West Delphi group. *Epilepsia*. 2004; 45: 1416-1428.
2. Pellock JM, Hrachovy R, Shinnar S, et al. Infantile spasms A U S. consensus report. *Epilepsia*. 2010; 51: 2175-2189.
3. Aicardi J. Infantile spasms and related syndromes. *Epilepsy in Children The International Review of Child Neurology*. Second edition. New York Raven Press 1994.
4. Riikonen R. Epidemiological data of West syndrome in Finland. *Brain Dev*. 2001; 23: 539- 541.
5. Ludvigsson P, Ólafsson E, Sigurðardóttir S, et al. Epidemiologic features of infantile spasms in Iceland. *Epilepsia*. 1994; 35: 802- 805.
6. O Callaghan FJK, Lux AL, Darke K, et al. The effect of lead time to treatment and of age of onset on developmental outcome at 4 years in infantile spasms: Evidence from the United Kingdom Infantile Spasms Study. *Epilepsia*. 2011; 52: 1359-1364.
7. Primec ZR, Stare J, Neubauer D. The risk of lower mental outcome in infantile spasms increases after three weeks of hypsarrhythmia duration. *Epilepsia*. 2006; 47: 2202-2205.
8. Riikonen RS. Favourable prognostic factors with infantile spasms. *Eur J Paediatr Neurol*. 2010; 14: 13-18.
9. Go CY, Mackay MT, Weiss SK, et al. Evidence based guideline update Medical treatment of infantile spasms Report of the Guideline Development Subcommittee of the American Academy of Neurology and the Practice Committee of the Child Neurology Society. *Neurology*. 2012; 78: 1974 -1980.

10. Hrachovy RA, Frost JD Jr. Infantile epileptic encephalopathy with hypsarrhythmia infantile spasms West syndrome. *J Clin Neurophysiol.* 2003; 20: 408-425.
11. Hrachovy RA, Frost JD Jr, Kellaway P, et al. Double blind study of ACTH vs prednisone therapy in infantile spasms. *J Pediatr.* 1983; 103: 641-645.
12. Hrachovy RA, Frost JD Jr, Glaze DG. High dose long duration versus low dose short duration corticotropin therapy for infantile spasms. *J Pediatr.* 1994; 124: 803-806.
13. Baram TZ, Mitchell WG, Tournay A, et al. High dose corticotropin ACTH versus prednisone for infantile spasms a prospective randomized blinded study. *Pediatrics.* 1996; 97: 375-379.
14. Vigeveno F, Cilio MR. Vigabatrin versus ACTH as first-line treatment for infantile spasms a randomized prospective study. *Epilepsia.* 1997; 38: 1270-1274.
15. Riikonen R. A long term follow up study of 214 children with the syndrome of infantile spasms. *Neuropediatrics.* 1982; 13: 14-23.
16. Riikonen R. Infantile spasms Modern practical aspects. *Acta Paediatr Scand.* 1984; 73: 1-12.
17. Matsumoto A, Watanabe K, Negoro T, et al. Long term prognosis after infantile spasms A statistical study of prognostic factors in 200 cases. *Dev Med Child Neurol.* 1981; 23: 51-65.
18. Riikonen R. A long term follow up study of 214 children with the syndrome of infantile spasms. *Neuropediatrics.* 1982; 13: 14-23.
19. Okanishi T, Sugiura C, Saito Y, et al. Long term weekly ACTH therapy for relapsed West syndrome. *Pediatr Neurol.* 2008; 38: 445-449.
20. Inui T, Kobayashi T, Kobayashi S, et al. Efficacy of long term weekly ACTH therapy for intractable epilepsy. *Brain Dev.* 2015; 37: 449-454.
21. Nakata M, Kato T, Ide M, et al. Long term weekly ACTH therapy for relapsed West syndrome in tuberous sclerosis complex A case report. *Brain Dev.* 2016; 38: 431-434.
22. Fukushima K, Inoue Y, Fujiwara T, et al. Long term follow-up study of West syndrome associated with tuberous sclerosis. *Brain Dev.* 2001; 23: 698-704.
23. Winterkorn EB, Pulsifer MB, Thiele EA. Cognitive prognosis of patients with tuberous sclerosis complex. *Neurology.* 2007; 68: 62-64.
24. Cowan LD, Hudson LS. The epidemiology and natural history of infantile spasms. *J Child Neurol.* 1991; 6: 355-364.
25. Partikian A, Mitchell WG. Major adverse events associated with treatment of infantile spasms. *J Child Neurol.* 2007; 22: 1360-1366.
26. Lorusso P, Bottai A, Mangione E, et al. Low dose synthetic adrenocorticotropin hormone analog therapy for nephrotic patients results from a single center pilot study. *Int J Nephrol Renovasc Dis.* 2015; 8: 7-12.