

Neurofibromatosis type 1-associated brain tumors

Emily Cockey and Nicole J Ullrich*

Department of Neurology, Boston Children's Hospital, Boston, MA 02115, USA

Article Info

Article Notes

Received: July 08, 2016

Accepted: August 25, 2016

*Correspondence:

Nicole J Ullrich, Department of Neurology, Boston Children's Hospital, Boston, MA 02115, USA

E-mail: nicole.ullrich@childrens.harvard.edu

© 2016 Nicole J Ullrich. This article is distributed under the terms of the Creative Commons Attribution 4.0 International License.

Keywords

Neurofibromatosis type 1

brain tumors

Neurofibromin

Optic pathway gliomas (OPGs)

Brainstem gliomas

Glioblastomas

ABSTRACT

Neurofibromatosis type 1 (NF1) is a common autosomal dominant disorder that predisposes patients to develop benign and malignant neoplasms, most often due to a loss of function mutation in the neurofibromatosis type 1 (NF1) gene. Neurofibromin, the protein product of NF1, regulates the inactivation of the Ras pathway, and thus acts as a tumor suppressor. Located in neurons, Schwann cells, and melanocytes, a decrease in neurofibromin predisposes patients with NF1 to tumors in both the central and peripheral nervous systems. Interestingly, brain tumors associated with NF1 often follow a more benign course than their sporadic counterparts and are often found in different locations. Thus, these tumors are often observed without tumor-directed therapy, unless clinical progression is noted, and then they are treated with surgery, chemotherapy or radiation. Current treatment trials seek to create more targeted therapies for specific tumor types associated with NF1 in order to increase efficacy and decrease treatment-related morbidity. This review will examine the most common types of brain tumors associated with NF1, including pilocytic astrocytomas, optic pathway gliomas, brainstem gliomas and glioblastomas, and will provide an overview of the clinical implications, current treatments, and ongoing clinical trials for these tumors.

Neurofibromatosis Type 1

Background and Clinical Features

Neurofibromatosis type 1 (NF1) is the most common heritable brain tumor predisposition disorder, affecting an estimated 1 in 3,500 people worldwide.^{1,2} This neurocutaneous disorder is autosomal dominant with approximately 50% of cases classified as sporadic and 50% as familial.³ Although NF1 has 100% penetrance, the disease phenotype varies greatly within and between families and even within an individual, based on age and presumed genetic mosaicism.⁴⁻⁶ Diagnostic standards for NF1 have been established

Diagnostic criteria for NF1 ^{7*} :
1) 6 or more café au lait macules: > 5mm in prepubertal patients > 15mm in postpubertal patients
2) 2 or more neurofibromas of any type or 1 plexiform neurofibroma
3) Freckling in the inguinal or axillary regions
4) Optic nerve gliomas
5) 2 or more Lisch nodules (hamatomas of the iris)
6) A distinct osseous lesion (ex: sphenoid dysplasia) or thinning of the long bone cortex with or without pseudarthrosis
7) A first degree relative with NF1, as diagnosed by the above criteria

*Two or more clinical criteria must be present.

Table 1: Diagnostic criteria for NF1.

by consensus criteria (Table 1).⁷ Individuals with NF1 may also experience cognitive impairment, visual challenges, vascular abnormalities, and skeletal changes.^{4,8,9,10,11}

Molecular Genetics

In more than 95% of cases, NF1 is associated with a heterozygous loss of function mutation in the neurofibromatosis type 1(NF1) gene, located at 17q11.2.^{2,4,12} Over 800 different mutations in this gene or its protein product, neurofibromin, have been associated with NF1, with point mutations occurring in approximately 90% of cases and larger 1-1.5MB deletions occurring in approximately 10% of cases.^{2,4,11}

Neurofibromin is expressed in both neurons and non-neuronal tissue, especially oligodendrocytes, Schwann cells, and developing melanocytes.^{2,13} This protein product functions as a tumor suppressor by negatively regulating the p21-RAS proto-oncogene, and thus, by regulating cell proliferation.¹⁴ Neurofibromin accomplishes this task by speeding the transformation of active GTP-bound Ras to inactive GDP-bound Ras.^{15,16} This transformation down-regulates Ras-driven signal transduction pathways, including those that target mTOR, ras, raf, PI3K, AKT, MAPK, PKB and cyclic AMP.^{1,2} In addition, heterozygous loss of NF1 has been shown to affect proper actin cytoskeleton motility, leading to cells with irregular shapes, adhesion capabilities, and increased invasive cell motility.¹⁷

Role in Tumor Predisposition

Complete loss of NF1 gene function is thought to be causative in tumorigenesis.¹⁸ Since NF1 patients possess a heterozygous loss of NF1, they need only acquire one additional mutation to NF1 for tumorigenesis to occur.^{2,18} Due to the widespread expression of neurofibromin, NF1 patients may develop brain tumors, neurofibromas, malignant peripheral nerve sheath tumors (MPNSTs), carcinoid tumors, pheochromocytomas, leukemias and breast carcinomas, among others.^{19,20} This review will focus on NF1-associated brain tumors.

Optic pathway gliomas

Optic pathway gliomas (OPGs) affect 15-20% of individuals with NF1 and are therefore the single most common type of brain tumor associated with the disorder.^{9,10,21,22,23} Due to their location in the optic pathway, OPGs are not usually biopsied, and thus researchers and physicians are limited in their ability to classify OPGs and to determine which molecular pathways have been disrupted in the tumorous tissue. However, with the limited pathologic data available, the majority of OPGs are classified as pilocytic astrocytomas, and fewer as diffuse astrocytoma, NOS per the updated WHO classification schema, or glioblastomas.^{24,25}

Pilocytic astrocytomas in NF1 are WHO grade 1 gliomas characterized by biphasic architecture, Rosenthal fibers, and eosinophilic granular bodies.^{11,21,24} NF1-associated pilocytic astrocytomas are characterized by a complete lack of NF1 gene expression, and thus by increased GTP-bound p21-Ras.^{18,26} Pilocytic astrocytomas that occur sporadically do not have a loss of NF1 expression, suggesting a distinct mechanism of tumorigenesis.^{18,27}

Clinical implications

OPGs are more common in children with NF1 than in the general population.^{19,26,28} NF1-associated OPGs are often benign and are most often diagnosed and progressive in children between the ages of 2 and 6.^{10,29} Approximately 33% of NF1 patients with OPGs will develop symptoms, however, there is no way to predict which tumors will cause clinical impairment, expressed as a decline in visual acuity or visual function.^{9,10} According to the Optic Pathway Glioma Task Force, given the frequency of OPGs in children with NF1 and the much smaller proportion of individuals with clinical symptoms, "serial ophthalmological examinations, particularly in young children with NF1, are very important" however, "screening neuroimaging of asymptomatic children with NF1 for the detection of optic pathway gliomas has not been shown to improve clinical outcome".³⁰

While OPGs are more common in the NF1 population, they are also typically less aggressive than in the non-NF1 population.^{21,31} OPGs are more often found in the intraorbital optic nerve, or bilaterally in the optic nerves in patients with NF1 than they are in patients without NF1, who are more likely to have OPGs with optic tract involvement.^{28,31,32} In addition, individuals with NF1 are more likely to have symptoms of proptosis, precocious puberty, or visual acuity loss, while sporadic OPGs are more likely to be associated with hydrocephalus and nystagmus.³¹ Figure 1 demonstrates an optic pathway glioma found in a 10 year old girl who underwent neuroimaging for headaches. Visual acuity and visual fields were and remained stable without tumor directed therapy.

Treatment of OPGs is typically initiated when visual decline is noted, and then standard low grade glioma chemotherapy is the up-front treatment of choice. If there is an atypical appearance, surgery is considered.^{2,9} Following chemotherapy, 72% of NF1/OPG patients experience improvement and/or stabilization of visual acuity.¹⁰ The need for and response to second or third line treatments has not been assessed in this patient population; review of retrospective data is in process and a prospective, multicenter study is planned to collect these data.

Brainstem Gliomas

Brainstem gliomas are the second most common

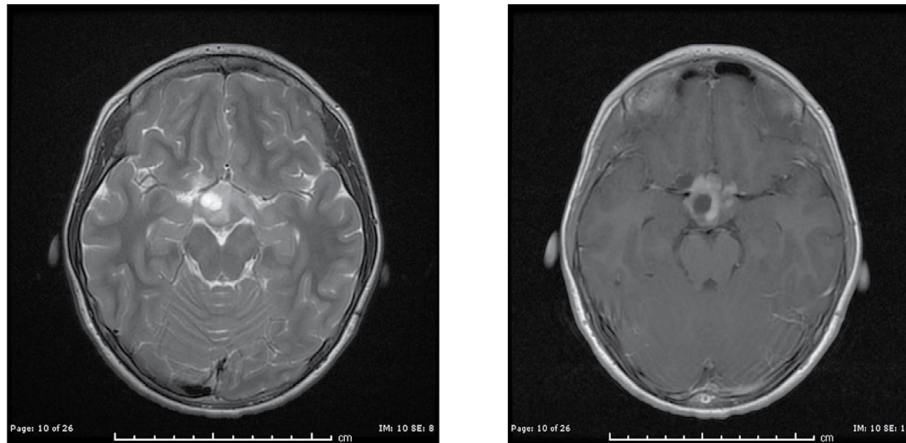


Figure 1: Axial T2 (left) and contrast-enhanced (right) magnetic resonance imaging of a 10 year old girl with NF1 who underwent imaging secondary to headaches. She was found to have a bilateral optic pathway glioma with chiasmal involvement and contrast enhancement. Visual acuity and visual fields were normal at the time this was detected and remained normal without tumor-directed therapy.

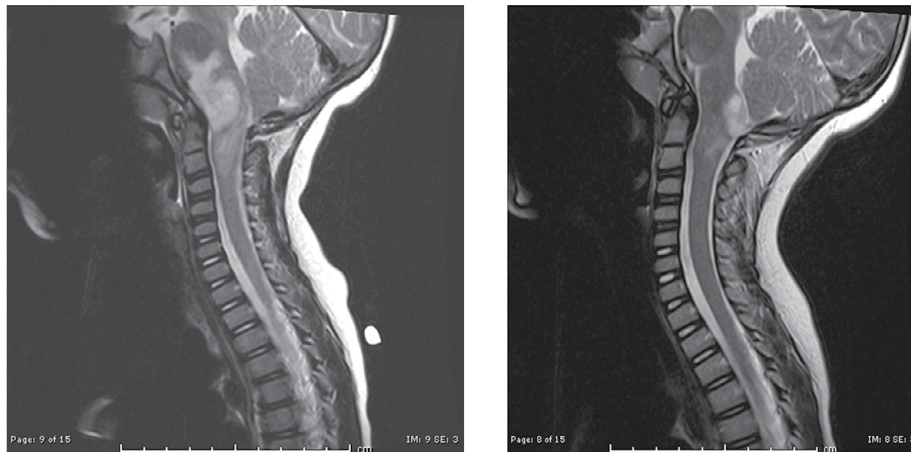


Figure 2: Sagittal T2-weighted MR imaging of a 4 year old boy with NF1 at baseline (left) and after two years of clinical and radiologic follow-up (right). He did not receive any tumor-directed therapy and the area of T2 hyperintensity and contrast enhancement (not shown) decreased without intervention.

type of brain tumor associated with NF1 and affect approximately 4% of patients.^{2,33} These tumors can be distinguished on imaging from the typical T2 hyperintense NF1-associated hamartomas or “NF spots”, because they cause focal or diffuse brainstem enlargement, exert mass effect and demonstrate variable contrast enhancement.^{23,34} Similar to OPGs, brainstem gliomas are rarely biopsied to prevent iatrogenic brainstem dysfunction, limiting the amount of tissue available to medical personnel for tumor classification and molecular research. Many of the tumors, however, are also classified as pilocytic astrocytomas.²²

Clinical implications

NF1-associated brainstem gliomas are often benign and progress clinically in only one-third, or less, of cases.³⁵ Children with NF1 and known brainstem gliomas are monitored clinically for development of symptoms

referable to the location, such as headache, hydrocephalus, or cranial neuropathies.³³ Similar to OPGs, NF1-associated brainstem gliomas are more indolent than those not associated with NF1 and most often do not require clinical intervention.^{2,36} Figure 2 demonstrates an expansive lesion in the cervico-medullary region that was detected on surveillance neuroimaging on a 4 year old boy with NF1, which on follow up imaging after 26 months had regressed significantly without any tumor-directed therapy. By contrast, brainstem gliomas in the non-NF1 population often cause death within 18 months of diagnosis.³³ Because many brainstem gliomas do not progress, physicians recommend consistent neurologic exams and imaging to detect progression, which would then suggest the need for treatment.³³

The typical location of NF1-associated brainstem gliomas also differs from the non-NF1 population. In NF1

patients, brainstem tumors are most often found in the lower medulla, followed by the pons, and finally in the midbrain, whereas in non-NF1 patients they are most prevalent in the pons and are typically more diffuse in nature and have a more aggressive clinical course.^{23,33,34}

Glioblastomas

Glioblastomas are high grade (WHO grade IV) gliomas that are more common in adults than in children and are thought to cause approximately 2% of gliomas in NF1 patients.^{21,27,36,37} Although these high grade gliomas are thus rare in NF1, the risk of developing a glioblastoma is five times greater in patients with NF1 than in the general population.³⁷

Clinical implications

NF1-associated glioblastomas are most often found in supratentorial brain regions.³⁸ Similar to the low-grade astrocytomas associated with NF1, glioblastomas have a better clinical course and overall survival than those not associated with NF1.²¹ However, even with a treatment series including surgery, radiation, and chemotherapy, NF1-associated glioblastomas have a 2-year survival rate of under 60%.²¹ Figure 3 demonstrates a right frontal glioblastoma in a 10 year old boy with history of NF1, which was treated with cranial irradiation and antiangiogenic therapy using bevacizumab.

Less frequent NF1-associated brain tumors

NF1-associated low grade gliomas are most commonly located in the optic system or brainstem, but they can also occur in the cerebellum and cerebral hemispheres.^{2,22} These low grade gliomas reside in locations more amenable to biopsy, so although they occur less frequently, there is more tissue available for investigation.

While pilocytic astrocytomas are the most common NF1-associated tumor class, other types of gliomas do occur,

which are similarly left untreated unless clinical symptoms arise.² The second most common NF1-associated tumors are low-grade subtype intermediate (LGS) tumors, followed by diffusely infiltrating astrocytomas.²⁴ Diffusely infiltrating astrocytomas are most often fibrillary astrocytomas, and tend to be less indolent than pilocytic astrocytomas and LGSs.²⁴ Rare cases of glioneuronal tumors (WHO grade 1), desmoplastic gangliomas, pilomyxoid astrocytomas (WHO grade II) and medulloblastomas (WHO grade IV) have also been reported in association with NF1.^{24,39}

Distinctions between NF1-associated and sporadic tumors

Common among many of the NF1-associated tumors is the fact that they have a more favorable course than their sporadic counterparts. The reasons behind this are not yet fully elucidated, but NF1-associated and non-NF1-associated tumors are thought to have distinct patterns of tumorigenesis; NF1-associated tumors develop following complete loss of function of NF1 whereas sporadic tumors do not.⁴⁰ Approximately 66% of sporadic tumors have a tandem duplication in BRAF which leads to a fusion between KIAA1549 and BRAF.⁴¹ KIAA1549:BRAF leads to hyperactivation of MAPK, a downstream product of Ras, and thus to aberrant cell proliferation.^{22,41} In fewer, typically higher grade II-IV gliomas, there is a mutation in BRAF that causes increased activation of MEK, another downstream element of the Ras pathway.^{22,42,43} Additionally, sporadic glioblastomas are associated with loss of TP53, amplified epidermal growth factor receptor (EGFR), loss of CDKN2A/p16, q10 deletions, and polysomy 7.⁴⁰ Differences in outcomes for NF1-related and sporadic tumors may also be explained by the fact that NF1-associated tumors often have concurrent mutations in other genes such as p53.³⁸

Treatment and Future Directions

The majority of NF1-associated brain tumors can be approached conservatively and often tumor-directed

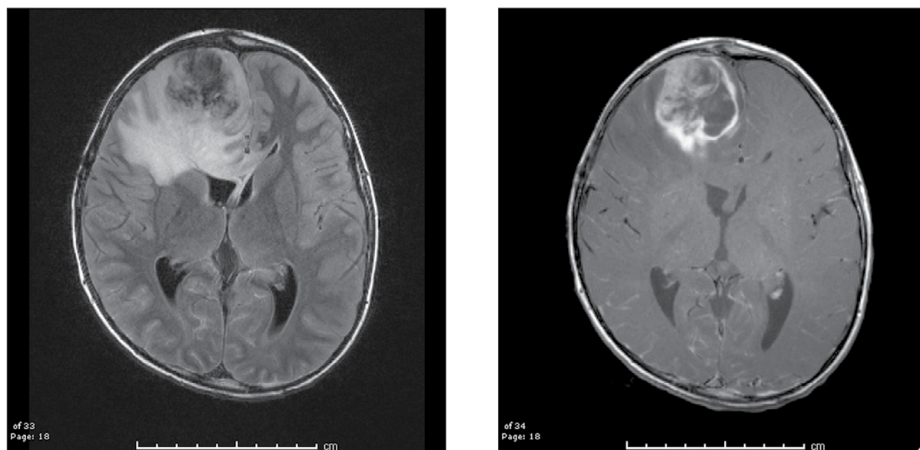


Figure 3: Axial FLAIR (left) and contrast enhanced (right) MR imaging of a 10 year old boy with NF1 and glioblastoma.

Clinical trial number	Drug	Drug type	Specific target in NF1 patients
NCT01158651	Everolimus	mTOR inhibitor	Low-grade gliomas
NCT02352844	Everolimus	mTOR inhibitor	Advanced solid malignancy
NCT00901849	Tarceva and Rapamycin	Anti-EGFR and mTOR inhibitor	Low-grade gliomas
NCT02285439	MEK162	MEK inhibitor	Low-grade gliomas, malignant brain neoplasms, soft tissue neoplasms
NCT01089101	Selumetinib	MEK 1/2 inhibitor	Recurrent or refractory low-grade gliomas
NCT02390752	PLX3397	Tyrosine kinase inhibitor	Refractory leukemia, refractory solid tumors

Table 2: Targeted clinical trials for NF1 associated central nervous system tumors.

treatment is not necessary.^{2,10} This course of action is taken for three reasons: 1) NF1-associated tumors are often benign, 2) it is difficult to predict which tumors will result in clinical symptoms, and 3) current therapies, especially radiation, may increase the risk of secondary tumors or malignant transformation of benign tumors.^{9,11,44} Surgery and/or chemotherapy are the typical treatments when clinical intervention does become necessary, due to the potentially deleterious side-effects noted after radiotherapy.^{2,9,10,11}

Radiotherapy may increase the chance of moyamoya syndrome, malignant transformation of tumors, and secondary tumor formation, most often leading to sarcomas and breast cancers.^{11,44,45,46} Individuals with NF1 also represent an at risk-population with high risk of cognitive deficits after radiation.²

Targeted clinical trials which take advantage of the known molecular underpinnings of NF1 are underway, first using drugs that target the Ras pathway, which is often up-regulated in these neoplasms.⁴⁷ Promising clinical studies are investigating the efficacy of mTOR inhibitors, MEK inhibitors and tyrosine kinase inhibitors (Table 2). Such inhibitors have shown anti-tumor properties in murine models or are currently used to treat other, non-NF1 related tumors.^{47,48,49} If successful, these drugs will greatly advance the treatment of NF1-associated tumors.

Conclusions

In summary, individuals with NF1 are predisposed to a variety of brain tumors such as optic pathway gliomas, brainstem gliomas, and glioblastomas that tend to act more indolently than their sporadic counterparts. The majority of these tumors will not progress to cause clinical deficits and unfortunately, it is currently difficult to predict which tumors will progress. Due to these facts and given the toxicities associated with current chemotherapy, radiology, and surgery treatments, NF1-related tumors are often observed without intervention until clinical symptoms appear. Many promising trials are underway to create therapies that are more specifically targeted to NF1-related tumors, but future studies are still needed to better predict which tumors will remain benign and which will progress to cause clinical losses in order to start treatment as early as possible.

References

- Andersson LO, Borg H, Miller-Andersson M. Purification and characterization of human factor IX. *Thromb Res.* 1975;7(3):451-459.
- Osterud B, Flensburg R. Purification and some characteristics of the coagulation factor IX from human plasma. *Biochem J.* 1975;145(3):469-474.
- Pipe SW. Hemophilia: new protein therapeutics. *Hematology Am Soc Hematol Educ Program.* 2010;2010:203-209.
- Gailani D, Geng Y, Verhamme I, et al. The mechanism underlying activation of factor IX by factor XIa. *Thromb Res.* 2014;133 Suppl 1:S48-51.
- Chung KS, Madar DA, Goldsmith JC, et al. Purification and characterization of an abnormal factor IX (Christmas factor) molecule. *Factor IX Chapel Hill. J Clin Invest.* 1978;62(5):1078-1085.
- Walker RK, Krishnaswamy S. The activation of prothrombin by the prothrombinase complex. The contribution of the substrate-membrane interaction to catalysis. *J Biol Chem.* 1994;269(44):27441-27450.
- Krishnaswamy S. Prothrombinase complex assembly. Contributions of protein-protein and protein-membrane interactions toward complex formation. *J Biol Chem.* 1990;265(7):3708-3718.
- Pilli VS, Plautz WE, Monroe DM, et al. A novel one-step purification of mouse factor IX. *Thromb Res.* 2016;139:125-126.
- Bajaj SP, Rapaport SI, Prodanos C. A simplified procedure for purification of human prothrombin, factor IX and factor X. *Preparative biochemistry.* 1981;11(4):397-412.
- Chattopadhyay R, Sengupta T, Majumder R. Inhibition of intrinsic Xase by protein S: a novel regulatory role of protein S independent of activated protein C. *Arterioscler Thromb Vasc Biol.* 2012;32(10):2387-2393.
- Liebman HA, Limentani SA, Furie BC, et al. Immunoaffinity purification of factor IX (Christmas factor) by using conformation-specific antibodies directed against the factor IX-metal complex. *Proc Natl Acad Sci U S A.* 1985;82(11):3879-3883.
- CHRISTMAS disease. *Br Med J.* 1952;2(4799):1405-1406.
- Mannucci PM, Tuddenham EG. The hemophilias: progress and problems. *Semin Hematol.* 1999;36(4 Suppl 7):104-117.
- Mannucci PM, Tuddenham EG. The hemophilias--from royal genes to gene therapy. *N Engl J Med.* 2001;344(23):1773-1779.
- Sabatino DE, Nichols TC, Merricks E, et al. Animal models of hemophilia. *Prog Mol Biol Transl Sci.* 2012;105:151-209.
- Bond M, Jankowski M, Patel H, et al. Biochemical characterization of recombinant factor IX. *Seminars in hematology.* 1998;35(2 Suppl 2):11-17.
- Liu J, Jonebring A, Hagstrom J, et al. Improved expression of recombinant human factor IX by co-expression of GGXX, VKOR and furin. *The protein journal.* 2014;33(2):174-183.
- Harrison S, Adamson S, Bonam D, et al. The manufacturing process for recombinant factor IX. *Seminars in hematology.* 1998;35(2 Suppl 2):4-10.

19. Emeis JJ, Jirouskova M, Muchitsch EM, et al. A guide to murine coagulation factor structure, function, assays, and genetic alterations. *J Thromb Haemost*. 2007;5(4):670-679.
20. Sarkar G, Koeberl DD, Sommer SS. Direct sequencing of the activation peptide and the catalytic domain of the factor IX gene in six species. *Genomics*. 1990;6(1):133-143.
21. Nichols TC, Dillow AM, Franck HW, et al. Protein replacement therapy and gene transfer in canine models of hemophilia A, hemophilia B, von willebrand disease, and factor VII deficiency. *ILAR J*. 2009;50(2):144-167.
22. Lozier JN, Nichols TC. Animal models of hemophilia and related bleeding disorders. *Semin Hematol*. 2013;50(2):175-184.
23. Chandler RJ, Venditti CP. A barrel of monkeys: scAAV8 gene therapy for hemophilia in nonhuman primates. *Mol Ther*. 2011;19(5):826-827.
24. Feng D, Stafford KA, Broze GJ, et al. Evidence of clinically significant extravascular stores of factor IX. *J Thromb Haemost*. 2013;11(12):2176-2178.
25. Hagel L, & GJ, Sofer G. Development, Manufacturing, Validation and Economics. *Handbook of Process Chromatography*. 2008; Second Edition.
26. Orlova NA, Kovnir SV, Vorobiev, II, et al. Coagulation Factor IX for Hemophilia B Therapy. *Acta naturae*. 2012;4(2):62-73.
27. Van Cott KE, Butler SP, Russell CG, et al. Transgenic pigs as bioreactors: a comparison of gamma-carboxylation of glutamic acid in recombinant human protein C and factor IX by the mammary gland. *Genetic analysis : biomolecular engineering*. 1999;15(3-5):155-160.